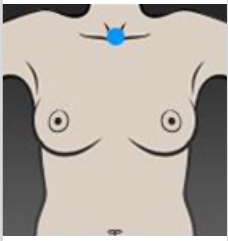
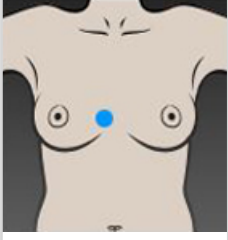
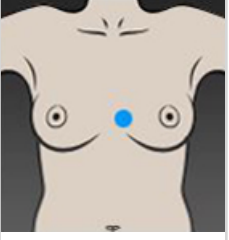
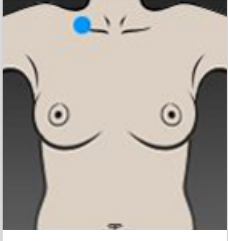
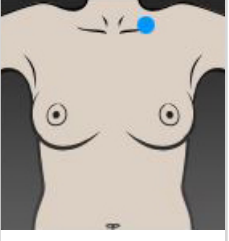
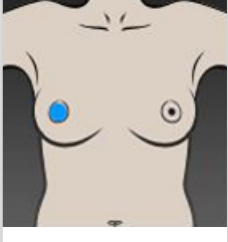
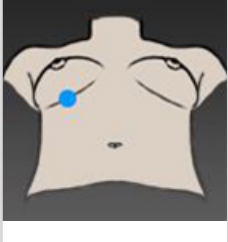
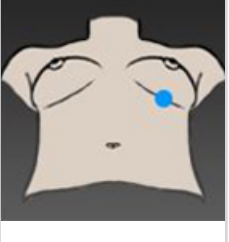
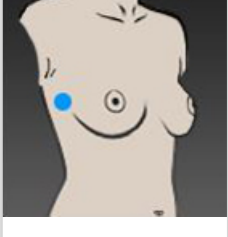


LANDMARKS - Breast Sculptor

Sn	Sternal notch				
MMF(r)	Medial Mammary Fold (Right)		MMF(l)	Medial Mammary Fold (Left)	
C(r)	Clavide (Right)		c(l)	Clavide (Left)	
N(r)	Nipple (Right)		n(l)	Nipple (Left)	
A(r)	Areola (Right)		A(l)	Areola (Left)	
IMF(r)	Inframammary (Right)		IMF(l)	Inframammary (Left)	
LMF(r)	Lateral Mammary Fold (Right)		LMF(l)	Lateral Mammary Fold (Left)	